

Transient osteoporosis of the knee in pregnancy: a case report and literature review

Ferenc, Thomas; Matković, Andro; Jurjević, Nikolina; Perić, Vitorio; Šebečić, Božidar; Vidjak, Vinko

Source / Izvornik: **Radiology Case Reports, 2025, 20, 1328 - 1332**

Journal article, Published version


Rad u časopisu, Objavljena verzija rada (izdavačev PDF)

<https://doi.org/10.1016/j.radcr.2024.11.033>

Permanent link / Trajna poveznica: <https://urn.nsk.hr/urn:nbn:hr:264:237894>

Rights / Prava: [In copyright](#)/[Zaštićeno autorskim pravom.](#)

Download date / Datum preuzimanja: **2025-03-10**



Repository / Repozitorij:

[Merkur University Hospital Repository](#)

Available online at www.sciencedirect.com

ScienceDirect

journal homepage: www.elsevier.com/locate/radcr

Case Report

Transient osteoporosis of the knee in pregnancy: A case report and literature review ☆☆☆

Thomas Ferenc, MD^{a,*}, Andro Matković, MD^a, Nikolina Jurjević, MD^a, Vitorio Perić, MD^a, Božidar Šebečić, MD, PhD^{b,c}, Vinko Vidjak, MD, PhD^{a,c}

^a Department of Diagnostic and Interventional Radiology, University Hospital Merkur, 10000, Zagreb, Croatia

^b Department of General and Sports Traumatology and Orthopedic Surgery, University Hospital Merkur, 10000, Zagreb, Croatia

^c School of Medicine, University of Zagreb, 10000, Zagreb, Croatia

ARTICLE INFO

Article history:

Received 8 October 2024

Revised 3 November 2024

Accepted 11 November 2024

Available online 12 December 2024

Keywords:

Transient osteoporosis

Knee

Pregnancy

ABSTRACT

Transient osteoporosis (TO) is a self-limiting bone disorder with a benign clinical course and unknown etiology, typically manifesting in the third trimester of pregnancy. There are only a few documented cases of TO in pregnant women involving the knee joint. We report a 38-year-old female patient in the third trimester of pregnancy who presented with an 8-week history of progressive worsening of the right knee pain. Clinical and magnetic resonance imaging findings were suggestive of TO with complete resolution of symptoms and imaging findings within several months following the onset of the symptoms. Clinicians need to include TO in their differential diagnosis when treating pregnant women with knee pain.

© 2024 The Authors. Published by Elsevier Inc. on behalf of University of Washington.

This is an open access article under the CC BY-NC-ND license

(<http://creativecommons.org/licenses/by-nc-nd/4.0/>)

Introduction

Transient osteoporosis (TO) is a rare, self-limiting bone disorder of unknown etiology that typically occurs in the third trimester of pregnancy and young or middle-aged men [1–5]. Patients usually present with joint pain and reduced range of motion (ROM) without a previous history of bone trauma [3,5,6]. The hip joint is typically affected in pregnant women, more commonly the left one [3,7]. TO may also seldom affect knee, ankle, and foot joints [1,6]. In pregnant patients with

TO, knee involvement is usually in combination with the hip, and there are only a few reports of isolated knee cases [3–6,8]. Herein, we report a case of a pregnant woman with isolated right knee TO with a literature review of all reported cases.

Case report

A 38-year-old female patient in the 38th week of pregnancy (gravida 3, para 2) presented with an 8-week history of right

☆ Competing Interests: The authors declare that they have no known competing financial interests or personal relationships that could have appeared to influence the work reported in this paper.

☆☆ Acknowledgments: No funding received.

* Corresponding author.

E-mail address: thomas.ferenc95@gmail.com (T. Ferenc).

<https://doi.org/10.1016/j.radcr.2024.11.033>

1930-0433/© 2024 The Authors. Published by Elsevier Inc. on behalf of University of Washington. This is an open access article under the CC BY-NC-ND license (<http://creativecommons.org/licenses/by-nc-nd/4.0/>)

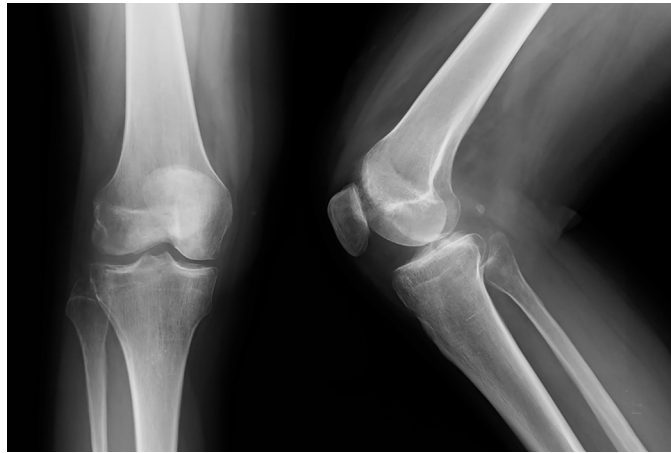

Fig. 1 – Plain radiographs of the knee with patchy bone demineralization of the lateral femoral condyle and tibia.

knee pain, predominantly on the lateral side. During the present pregnancy, the patient was SARS-CoV-2 positive and experienced mild symptoms. Otherwise, the pregnancy was uneventful. Previous pregnancies were also unremarkable and were full-term. The patient reported no previous history of trauma, joint disorders, or corticosteroid use. Her family history of rheumatologic disease spectrum was unremarkable. During the 8-week interval, the patient's symptoms gradually worsened until she was unable to bear her weight on her right leg and was compelled to use a walking aid. At the admission, clinical examination demonstrated palpatory tenderness and swelling over the lateral femoral condyle and tibia. A limited ROM was also noticed due to pain. Tests for anterior cruciate ligament (ACL) or meniscal rupture were negative. Laboratory parameters were within normal range apart from the D-dimer levels (1,29; reference level <0,50 mg/L). She was admitted to the hospital and low molecular weight heparin (LMWH) was administered. During hospitalization, the patient was twice referred to a venous Doppler ultrasound evaluation; however, there were no signs of deep vein thrombosis and LMWH was discontinued after the second examination. A knee ultrasound demonstrated minor intraarticular effusion. Following the spontaneous and uneventful childbirth, the patient was referred to a knee X-ray that displayed patchy bone demineralization of the lateral femoral condyle and tibia, without any signs of fracture, joint space reduction, or erosions (Fig. 1). On the eighth day postpartum, the patient was referred to a right knee MRI that showed a diffuse decrease in signal intensity of the lateral femoral condyle on the T1-weighted (T1W) images and a diffuse increase in signal intensity of the same area on the proton density (PD) weighted images with fat saturation (Fig. 2). The findings were interpreted as bone marrow edema. Other findings included minor bone edema of the lateral tibia condyle and suprapatellar knee effusion. There were no signs of meniscal, cartilage, or ligamentous damage. The diagnosis of TO was suspected. The treatment was conservative and consisted of analgesics, limited weight bearing using crutches, and avoiding activities that increase pain. In the following months, the patient reported that

the pain gradually resolved, and 3 months after labor it completely resolved. The follow-up MRI was planned 3-6 months after the initial examination; however, the patient did not follow the recommendation. The patient appeared on a follow-up MRI 12 months after the initial examination, demonstrating complete resolution of the earlier findings (Fig. 3).

Discussion

TO is a self-limiting bone disorder of unknown etiology and a benign clinical course, typically occurring in the third trimester of pregnancy [6,7]. The most affected joint is the hip, followed by the rare involvement of the knee, ankle, and foot [1,2,4–7]. Hip involvement was reported in 76% of cases [1,4,5], more commonly in the left one, while bilateral involvement occurs in 25-30% of individuals [2,7]. Simultaneous TO of both hips has been reported almost solely in pregnant patients [6]. The symptoms of TO were first documented by Babinsky and Fromen in 1916, whereas in 1959 Curtiss and Kincaid reported the first cases of TO in women in the third trimester of pregnancy [1,5–7,9]. In 1968 Lequesue was the first to introduce the term “transient osteoporosis” [1,6]. Various other terms are used to describe this clinical entity: transient demineralization, transient bone marrow edema, transient regional osteoporosis, reflex sympathetic dystrophy, etc. [5,6].

A literature review was conducted in PubMed and Scopus with no restrictions regarding the language or the year of publication. The selected keywords were: “Transient osteoporosis” AND “Knee” AND “Pregnancy”. Out of 27 research papers found, 11 case reports included TO of the knee – 7 pregnant patients presented with isolated knee involvement and 4 with knee involvement due to migratory disease [1,2,7,9]. The migration of the disease is usually from proximal to distal joints, occurring in between 5 and 41% of cases [1,6]. Out of 7 isolated knee cases, 5 pregnant women presented with TO of both knees and 2 with right knee symptoms. The list of reported patients with TO confined to the knee is displayed in

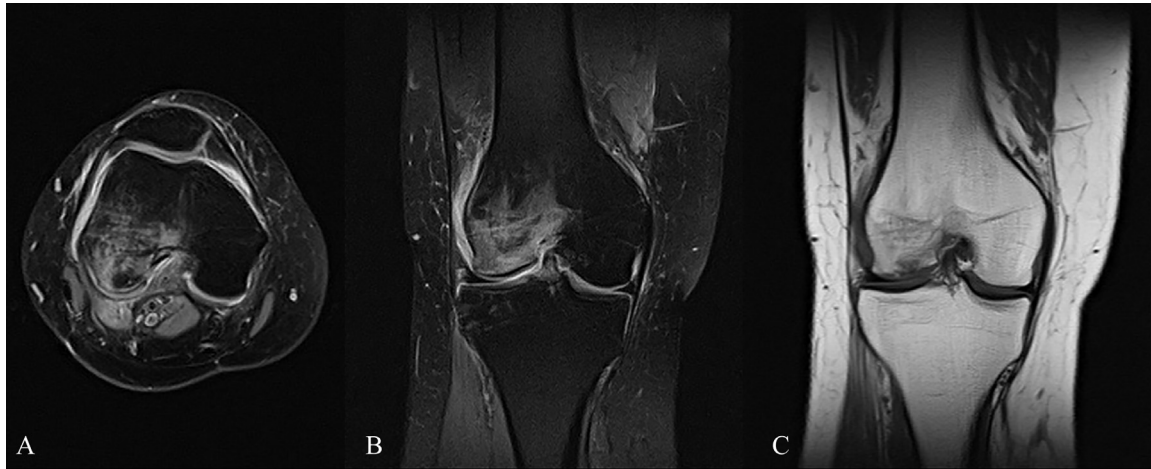

Fig. 2 – Initial MRI images (A) axial plane, PD fat-saturated sequences; (B) coronal plane, PD fat-saturated sequences; (C) coronal plane, T1W image.

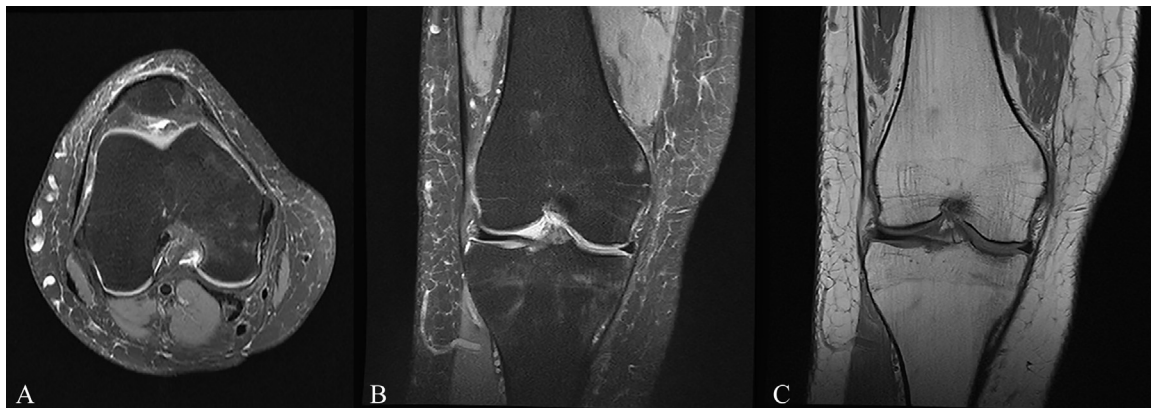

Fig. 3 – Follow-up MRI images (A) axial plane, PD fat-saturated sequences; (B) coronal plane, PD fat-saturated sequences; (C) coronal plane, T1W image.

Table 1. According to the analyzed literature, the median maternal age was 36 years (interquartile range (IQR), 36-39) with 71% of cases occurring during the first pregnancy. Three pregnancies were the result of in-vitro fertilization (IVF), and all pregnancies were uneventful. In all women onset of symptoms started in the third trimester of pregnancy and the diagnosis was confirmed using MRI. The most common symptoms were progressively worsening joint pain, tenderness, and limited ROM, with or without intraarticular effusion. Treatment was conservative (analgesics, calcitonin, calcium and vitamin D supplements, limited weight bearing, rest). The complete resolution of symptoms occurred after a median of 12 weeks (IQR 10-25) or 3 months. A supracondylar femoral fracture complicated one case. The data about delivery was available in 5 cases, and 4 newborns were term.

According to several authors, the usual median duration of symptoms is between 3 to 8 months; however, it may last longer up to 1 year [3,7]. Due to decreased mineralization during TO, bone is more susceptible to microfractures which are considered to be the main cause of pain during weight bearing [7]. There are several factors or theories proposed

as possible explanations for the higher prevalence of TO in pregnant women: genetic predisposition; vitamin C and D deficiency; increased body weight; venous congestion with localized hyperemia, bone medullary hypertension, and microvascular ischemia; subperiosteal and subchondral fat embolism; fetal obturator nerve compression with selective denervation; physiological increase in adrenal cortex activity, and the cytomegalovirus (CMV) infection [1-3,5-7,9].

Bone demineralization in women is usually associated with estrogen deficiency, however, it remains unclear why TO changes occur despite surplus levels of estrogen during gestation [7,9]. An average loss of 30 g of calcium was noted during the pregnancy due to the mineralization of the fetal skeleton, with 80% of the amount lost during the third trimester [1,6,10]. However, the negative calcium balance during gestation and puerperium has yet to be determined as a potential cause since it cannot be associated with selective demineralization [9]. Some authors are against breastfeeding in women with TO due to the observation of a rapid increase in bone mineral density after cessation of lactation [7]. An increase in body weight during pregnancy leads to bone and joint overload. In

Table 1 – The list of reported cases of knee TO during pregnancy.

N	Country/ year	Age	Gravidity/ parity	Pregnancy course	Onset of symptoms (week/ trimester of pregnancy)	Uni-/ bilateral	Treatment	Compli- cations	Resolution (weeks)	Ref.
1	New Zealand, 2001	36	1/0	IVF, uneventful	30, third	bilateral	conservative	none	12	[4]
2	Greece, 2009	42	1/0	IVF, uneventful	27, third	bilateral	conservative	none	40	[6]
3	Spain, 2009	32	1/0	uneventful	NM, third	right	conservative	supracon- dylar femoral fracture	14	[8]
4	UK, 2010	36	1/0	uneventful	NM, third	right	conservative	none	12	[3]
5	Switzerland, 2012	39	3/1	uneventful	39, third	bilateral	conservative	none	8	[5]
6	Spain, 2024	38	2/0	IVF, uneventful	31, third	bilateral	conservative	none	36	[14]
7	Spain, 2024	35	1/0	uneventful	26, third	bilateral	conservative	none	4	[14]
8	Croatia, 2024	38	3/2	COVID-19, uneventful	38, third	right	conservative	none	12	This case

*NM = not mentioned, IVF = in-vitro fertilization

some cases, physiological bone resorption, weight overload, and hormonal status may be the cause of bone microfractures and initiate TO [6]. One of the earlier-mentioned theories for TO is venous congestion followed by localized hyperemia, bone medullary hypertension, and microvascular ischemia. Biopsies of the affected bones have displayed an increased number of red blood cells which is also a physiological occurrence in pregnancy [3]. Another proposed theory was fetal pelvic nerve compression leading to selective denervation and selective bone demineralization. In animal studies, complete nerve transections failed to support this thesis [3]. However, compression of vascular structures in proximity to the pelvic nerve plexuses may lead to neural ischemia and bone demineralization [3]. Adrenal cortex activity physiologically increases during gestation with amplified bone reabsorption which may produce areas of bone demineralization [3]. CMV infection in pregnancy was also suggested as an associative factor with TO because bone marrow is a known reservoir for the virus [2]. Furthermore, there is also a reported case of knee TO following trauma, however in a middle-aged man [11].

The mainstay for the diagnosis of TO is MRI [4]. Characteristic findings are decreased signal intensity on T1W images and increased signal intensity on T2-weighted (T2W) images that represent bone marrow edema [3,5,6,8]. In our case, PD sequences with fat saturation were used. MRI may detect the pathological bone signal 48 hours following the onset of symptoms [1,8]. Initial plain radiographs in patients with TO often display normal mineralization with focal or diffuse osteopenia becoming apparent after 3 to 8 weeks [4–7,9]. The intraarticular spaces are preserved without erosions, subchondral collapse, or cavitations [4,7]. Other imaging methods that can be used for the assessment of TO are skeletal scintigraphy with increased uptake of the radioisotope around the affected joint (usually positive within the first few days after the onset of symptoms) [5–7] or in our case ultrasound. One American case study used postpartum bone densitometry to determine mineralization of the affected hip by TO. It revealed a 20% decrease

in femoral neck density compared to the match-aged controls 3 to 5 months following the onset of symptoms [12]. Biochemical laboratory values are usually within the normal range, seldom non-specific with mild elevation of erythrocyte sedimentation rate or C-reactive protein level and globulin levels [4,5].

The differential diagnosis of TO is mainly based on the exclusion. It includes avascular necrosis (AVN), regional migratory osteoporosis (RMO), infections, inflammatory joint disorders, primary or metastatic malignancy, stress fractures, multiple myeloma, pigmented villonodular synovitis, and synovial osteochondromatosis [1–3,6,7,9]. AVN and RMO are the most important pitfalls in the differential diagnosis of TO [1,9]. AVN can be distinguished from TO by showing joint space reduction and the “double line” MRI sign formed at the demarcation line, therefore unnecessary interventions such as surgical decompression or arthroplasty can be avoided [1,2]. RMO significantly overlaps with TO on imaging; however, it predominantly affects middle-aged men (50–60 years of age), and more commonly knee, ankle, and foot joints, but rarely hips [2,7]. In addition to these entities, subchondral insufficiency fracture of the knee (SIFK), earlier known as spontaneous osteonecrosis of the knee (SONK), is a type of stress fracture that should also be considered in differential diagnosis. Besides bone marrow edema, a subchondral hypointense line on T2W images and PD sequences is a typical finding in SIFK and it can be followed parallel or curvilinear to the subchondral plate, only several millimeters away from the epiphyseal surface [13]. Mild contour deformity or flattening of the epiphysis may also be seen and associated findings in SIFK are often meniscal abnormalities and various degrees of osteoarthritis, all of which are not typically visualized in patients with TO [13].

Since TO is a self-limiting condition, conservative treatment is advised in pregnancy, mainly consisting of analgesics, limited weight bearing, and physiotherapy (isometric exercises) [1,3,4]. In isolated reports corticosteroids, bisphosphonates, calcitonin, and vitamin D supplements were used [3,5,6]. Several authors recommend avoiding pain relievers [5], calcitonin, and bisphosphonates [3].

Conclusion

There are only several reports of knee TO in pregnant women, mainly occurring over the age of 35 with the onset of symptoms in the third trimester of the first pregnancy. Typical clinical findings are progressive worsening of knee pain (bilateral or unilateral) with limited ROM, usually followed by normal laboratory values. MRI is the mainstay for the diagnosis, whereas AVN and RMO are the most important disorders in the TO differential diagnosis. Conservative treatment is advised, and the expected resolution of symptoms is within 3 months.

Patient consent

Written informed consent was obtained from the patient for the publication of this case report and accompanying images. The anonymity of all clinical and graphical data used is ensured.

REFERENCES

- [1] Tasçı Bozbaş G, Gürer G, Şendur ÖF, Alkan AG. Migratory transient osteoporosis: atypical migration to the bilateral knee after childbirth. *Turk J Phys Med Rehab* 2016;62:178–81. doi:10.5606/tftrd.2016.01709.
- [2] Rozenbaum M, Boulman N, Rimar D, Kaly L, Rosner I, Slobodin G. Uncommon transient osteoporosis of pregnancy at multiple sites associated with cytomegalovirus infection: is there a link? *ISR Med Assoc J* 2011;13:709–11.
- [3] Lloyd J, Lewis M, Jones A. Transient osteoporosis of the knee in pregnancy. *J Knee Surg* 2010;19:121–3. doi:10.1055/s-0030-1248091.
- [4] Stamp L, McLean L, Stewart N, Birdsall M. Bilateral transient osteoporosis of the knee in pregnancy. *Ann Rheum Dis* 2001;60:721–2. doi:10.1136/ard.60.7.721a.
- [5] Charpidou T, Lang F, Langenegger T, Dedes KJ, Honegger C. Bilateral transient osteoporosis of the knee during pregnancy. *Arch Gynecol Obstet* 2013;287:1259–61. doi:10.1007/s00404-012-2628-4.
- [6] Ververidis AN, Drosos GI, Kazakos KJ, Xarchas KC, Verettas DA. Bilateral transient bone marrow edema or transient osteoporosis of the knee in pregnancy. *Knee Surg Sports Traumatol Arthrosc* 2009;17:1061–4. doi:10.1007/s00167-009-0781-5.
- [7] Ma FY, Falkenberg M. Case reports: transient osteoporosis of the hip: an atypical case. *Clin Orthop Relat Res* 2006;445:245–9. doi:10.1097/01.blo.0000201154.44572.d2.
- [8] García Renedo RJ, Ortiz Menéndez A, Giraldez Sánchez M, Ribera Zabalbeascoa J, Gonzalo DH. Gonalgia aguda en el embarazo: reporte de un caso de osteoporosis regional transitoria [Acute knee pain in pregnancy. Case report of Regional Transient Osteoporosis]. *Reumatol Clin* 2010;6:99–101. doi:10.1016/j.reuma.2009.04.012.
- [9] Kartal E, Sahin E, Dilek B, et al. Regional migratory osteoporosis: case report of a patient with neuropathic pain. *Rheumatol Int* 2011;31:1375–81. doi:10.1007/s00296-009-1256-1.
- [10] Kovacs CS. Calcium and bone metabolism in pregnancy and lactation. *J Clin Endocrinol Metab* 2001;86:2344–8. doi:10.1210/jcem.86.6.7575.
- [11] El Masry MA, Saha A, Calder SJ. Transient osteoporosis of the knee following trauma. *J Bone Joint Surg Br* 2005;87:1272–4. doi:10.1302/0301-620X.87B9.16631.
- [12] Funk JL, Shoback DM, Genant HK. Transient osteoporosis of the hip in pregnancy: natural history of changes in bone mineral density. *Clin Endocrinol (Oxf)* 1995;43:373–82. doi:10.1111/j.1365-2265.1995.tb02046.x.
- [13] Ochi J, Nozaki T, Nimura A, Yamaguchi T, Kitamura N. Subchondral insufficiency fracture of the knee: review of current concepts and radiological differential diagnoses. *Jpn J Radiol* 2022;40:443–57. doi:10.1007/s11604-021-01224-3.
- [14] Sánchez AA, Gálvez IMA, Aulestia NP, Muñoz BR, López JB. Transient osteoporosis of pregnancy: a case series. *Rev Colomb Reumatol* 2024;31:417–23. doi:10.1016/j.rcreue.2024.07.001.