

Complications of endoscopic CO2 laser surgery for laryngeal cancer and concepts of their management

Prgomet, Drago; Bačić, Antun; Prstačić, Ratko; Janjanin, Saša

Source / Izvornik: **Collegium antropologicum, 2013, 37, 1373 - 1378**


Journal article, Published version

Rad u časopisu, Objavljena verzija rada (izdavačev PDF)

Permanent link / Trajna poveznica: <https://um.nsk.hr/um:nbn:hr:264:439225>

Rights / Prava: [In copyright](#)/[Zaštićeno autorskim pravom.](#)

Download date / Datum preuzimanja: **2024-11-29**



Repository / Repozitorij:

[Merkur University Hospital Repository](#)

Complications of Endoscopic CO₂ Laser Surgery for Laryngeal Cancer and Concepts of their Management

Drago Prgomet¹, Antun Bačić², Ratko Prstačić¹ and Saša Janjanin¹

¹ University of Zagreb, University Hospital Center Zagreb, Department of ENT, Head & Neck Surgery, Zagreb, Croatia

² University of Zagreb, University Hospital »Merkur«, Department of ENT, Head & Neck Surgery, Zagreb, Croatia

ABSTRACT

Endoscopic CO₂ laser surgery (ELS) is a widely accepted treatment modality for early laryngeal cancer. Commonly reported advantages of ELS are good oncologic results with low incidence of complications. Although less common if compared with open procedures, complications following ELS can be very serious, even with lethal outcome. They can range from intraoperative endotracheal tube fire accidents to early and late postoperative sequels that require intensive medical treatment, blood transfusion, or revision surgery. We present our institutional experience, discuss the possible complications of ELS for laryngeal cancer, and outline the concepts of their treatment, with comprehensive literature review. Complications are more frequent following the treatment of supraglottic as compared to glottic cancer. If compared with open surgery, ELS for laryngeal cancer is associated with a lower incidence of complications. Every surgeon performing ELS should comply with particular strategies to avoid complications in the first place, and have a clear concept of their management if they occur.

Key words: endoscopic laser surgery, laryngeal cancer, CO₂ laser, complications

Introduction

There are three recommended modalities of treatment for early laryngeal cancer: radiotherapy, open laryngeal surgery and, more recently, endoscopic CO₂ laser surgery. Over the last two decades, many studies demonstrated that oncologic results of endoscopic laser surgery (ELS) are comparable to those of classic laryngeal partial procedures¹.

ELS is performed transorally under the microscope, and its primary objective is complete resection of the tumor while preserving as much functionality as possible². The main advantages of an endoscopic approach as compared with other treatment modalities are good oncologic results with reduced surgical trauma, conservation of the cartilaginous skeleton that allows for partial rescue surgery in most of the recurrent cases, avoidance of tracheotomy, rapid postoperative recovery with reduced hospitalization, and more favorable cost-effectiveness ratio. Additionally, most patients do not require postoperative use of a feeding tube³.

Most studies have also observed that ELS results in a reduced complication rate⁴; yet, complications occur in ELS as in any other type of surgery, some being followed by serious sequels or even lethal outcome⁵. Also, there are some complications of ELS that have never been experienced with open procedures, like incidental burns of trachea, combustion of the endotracheal tube, skin burns, or injuries to the eyes⁶.

Since the early 1970s and the first description of ELS in the treatment of upper airway tumors, many articles have been published on oncologic results of this type of surgery. Most of these series have also reported their complication rates. However, just a few of them focused primarily on complications that can develop with the use of ELS and methods of their treatment. Unlike other authors, we tried to review the acute and long-term complications that can occur with the use of laser-assisted surgery for laryngeal cancer, and to summarize the concepts of their management. As ELS is gaining more popularity,

surgeons performing this technique must recognize complications and know how to handle them. Therefore, the primary aim of this article was to review all types of complications that occur in ELS, and at the end we briefly supported data by our institutional results.

Types of complications

Local infection. Local postoperative infection occurs in less than 1 % of patients, most commonly in those with previous radiotherapy or with other concomitant systemic diseases like diabetes mellitus. In most cases, it presents as early perichondritis and is prone to develop mostly in patients with broadly exposed laryngeal cartilage. The real neck abscess is very rare. Presenting symptoms are typical for inflammation: neck pain, unpleasant smell, and a red swollen skin above the laryngeal prominence. The standard of treatment is i.v. antibiotic therapy for 3 weeks. In case of long lasting infection without appropriate response to antibiotic therapy, a cartilage remnant as the cause of infection should be considered, requiring exploration and extraction of the remnant using microlaryngoscopy.

Emphysema and cervical leakage. Overresection of the fat tissue of the cryothyroid membrane, pre-epiglottic space, tumors of the anterior commissure, or tracheal injury can cause emphysema. Small emphysema usually disappears in several days without any therapy, while bigger or mediastinal emphysema requires tracheotomy and sometimes thoracic drainage.

Postoperative mucosal edema. Immediate postoperative dyspnea is the result of soft tissue edema, which is particularly common in patients with previous radiotherapy. Frequently found is medial protrusion of the swollen aryepiglottic fold after pyriform sinus tumor resection. Patients with significant edema should be admitted to intensive care unit for corticosteroid injections and permanent surveillance. Less than 2 % of patients need temporary tracheostomy⁷.

Postoperative hemorrhage. Postoperative hemorrhage is the most serious complication. Postoperative hemorrhage is infrequent in glottic tumors, but is more common in supraglottic and hypopharyngeal tumors, even following very small resections. In almost half of cases, the blood in patient saliva is the only presenting symptom; in these patients control laryngeal fiberoendoscopy can be performed and most of such bleedings will spontaneously cease soon thereafter. Cases that are more serious require surgical revision and endoscopic coagulation. Difficult intubation is expected due to limited visualization and tracheotomy may sometimes be necessary. The most efficient tool to stop the bleeding is hemostatic clip; if it is not possible to apply, electrocautery can be used. In general anesthesia, the low blood pressure and retraction of the vascular vessel prevent visualization of the site of bleeding, which is mostly in the region of the upper laryngeal artery. If the site of bleeding cannot be identified, one should try to provoke bleeding with external pressure upon the larynx, explore the operated region using

meticulous suction, and increase blood pressure in cooperation with the anesthesiologist. The final solution would be prophylactic electrocoagulation of blood vessels at the level of aryepiglottic fold if all previous attempts were unsuccessful. Extremely rarely, it is necessary to ligate external carotid artery or perform supraseductive embolization. If there is a doubt of possible bleeding, optimal solution for the patient is intubation for 24 hours in intensive care unit, very rarely tracheostomy should be performed in advance. Extremely dangerous is late bleeding (around 10 days after surgery) because patients are usually at home without appropriate urgent medical care, and fatal outcome is more likely to occur.

Aspiration. In endoscopic partial laryngectomy – especially supraglottic – resection of the natural protective barriers such as the epiglottis, aryepiglottic folds and false vocal folds can lead to aspiration in either latent or manifest clinical form. Deglutition assessment should be performed using the M.D. Anderson Dysphagia Inventory (MDADI), video nasal endoscopic examination of swallowing (VEES) with blue food coloring and videofluoroscopy (VFS) during barium swallow. Swallowing depends on the type of surgical treatment, the conditions and the mobility of the esophagus remnant, consistency of the bolus, patient motivation, radiotherapy, and possible comorbidities. Open approach laryngectomies more often result in aspiration than endoscopic resections. In open partial laryngectomy, removal of the carcinoma implies resection or detachment of the uninvolved extrinsic infrahyoid muscle, hyoid bone, part of laryngeal framework and healthy soft tissue, tongue base, superior laryngeal nerve (posterior descending branch of the internal division of the nerve), tracheostomy and feeding tube. Transection of the superior laryngeal nerve leads to the sensory field deficit that interferes with bolus detection, and to weakening of the glottic closure response.

Pneumonia. In most studies, the incidence of both early postoperative and late pneumonia ranges between 3 and 7 %^{5,8}. Patient age, type and extent of surgical resection, as well as preoperative pulmonary status have been shown to be important prognostic factors for the frequency of this complication. Common treatment is antibiotic therapy, but sometimes – in cases of recurrent pneumonia – it is necessary to perform temporary tracheostomy and place a feeding tube for a longer period of time. Very rarely, in cases resistant to all other treatments, the patient may need total laryngectomy as a definitive solution for aspiration.

Voice impairment. Voice impairment is not a real complication but, more or less, an expected side effect of the procedure. In most series, the incidence of permanent voice problems following endoscopic cordectomies is 40–50 % and strongly correlates with the extent of resection. The methods of voice assessment are crucial to objectify voice problems. The most important method of voice self-assessment is Voice Handicap Index (VHI). VHI measures the influence of voice problems on the patient's quality of life.

Objective methods of voice assessment are GRBAS scale, measurement of maximum phonation time (MPT) and acoustic analysis^{4,9}. The GRBAS (an acronym made from Grade, Roughness, Breathiness, Asthenia and Strain as the five main attributes of human voice) scale is perceptive voice analysis by two independent professionals experienced in vocal pathology. MPT is the maximum time for which a person can sustain a vowel sound when produced on one deep breath at a relatively comfortable pitch and loudness. It is an excellent and very simple test of glottic efficiency. Acoustic analysis is calculated by the four main parameters of the voice: average fundamental frequency (F0), jitter, shimmer, and noise to harmonics ratio.

Once diagnosed, voice impairment has to be treated in all patients. The treatment of choice is voice therapy, with surgical treatment being also necessary in some selected cases. Early initiation of voice therapy is recommended to prevent ineffective hyperkinetic compensatory mechanisms.

Granuloma. Granulomas (Figure 1) are non-cancerous growths composed mostly of granulation tissue and they reflect tissue response to injury and irritation. They frequently occur at 1–2 months after surgery, and it is not rare that they later disappear. It is important not to overlook the difference between granuloma and cancer recurrence. When endoscopic finding definitely indicates granuloma, no further treatment is necessary. However, if endoscopic finding is raising any suspicion, control laryngomicroscopy with biopsy and histologic analysis is necessary.

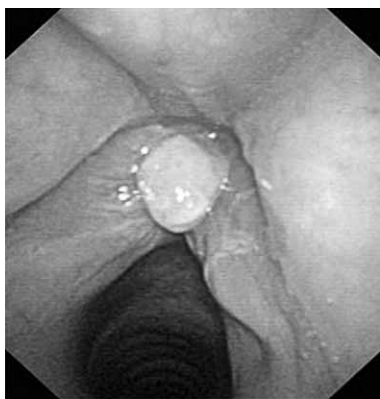

Fig. 1. Typical granuloma rising from the anterior commissure.

Synechiae. Synechiae (Figure 2) are more common after type VI cordectomy (resection of the anterior commissure and the anterior thirds of vocal folds)¹⁰. Also, synechiae are frequent in cases of revision procedures, especially in the area of cricoid cartilage. They usually cause voice disturbance, much less difficulty with breathing. The treatment of choice is laser resection following local application of Mitomycin C or laser resection and keel placement, depending on the extent of the synechiae¹¹.

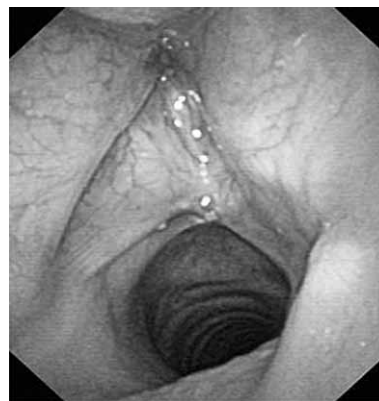

Fig. 2. Huge synechia of the anterior 2/3 of vocal folds.

Glottic gap. Glottic gap usually occurs after extended tumor resections and the main clinical symptom is voice impairment¹². If voice therapy fails, the treatment of choice is injection laryngoplasty with autologous fat for minor gaps or medialization thyroplasty for extended gaps.

Endotracheal tube fire. This is very rare, but also potentially fatal complication with the incidence of approximately 1/1300 procedures¹³. To reduce the risk of fire and consequent tracheobronchial tree combustion, some important safety precautions are recommended. The use of specially designed laser tubes is recommended in all cases of ELS. Furthermore, the tubes should be covered by soaked gauze or moist cottonoids in the areas of laser beam exposure, especially in the cuff region. Additionally, the reduction of oxygen saturation of the narcotic gas mixture during anesthesia is also an important preventive factor in avoiding this potentially lethal complication.

Results

During a twenty-year period (1988–2008), we operated 202 patients using ELS. All procedures were performed by three surgeons having extensive experience with the classical open procedures. There were 131 patients with glottic tumors (125 with Tis and T1 lesions, and 6 with T2) and 71 patients with supraglottic tumors (36 with T1 and 35 with T2). Therefore, we treated only T1 and T2 tumors of the larynx.

Postoperative complications developed in 41 (20.2 %) patients and were more frequent in supraglottic (24/71; 34 %) than glottic tumors (17/131; 13 %). There was one case of intraoperative endotracheal tube fire, fortunately just with localized superficial burn of the tracheal mucosa and without permanent consequences. Four patients developed perichondritis and local infections that were treated with antibiotic therapy; five patients developed emphysema (all following resection of the anterior commissure or the pre-epiglottic space); seven patients had significant postoperative mucosal edema necessitating temporary tracheostomy in two cases. Postoperative

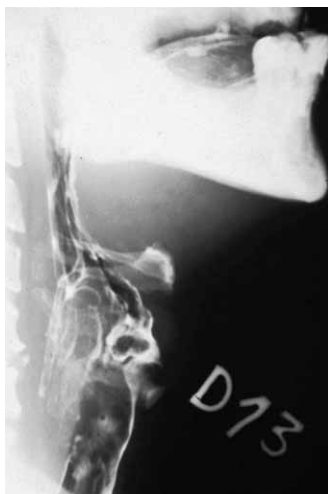

Fig. 3. Videofluoroscopy during barium swallow showing aspiration in a patient with endoscopic supraglottic laryngectomy of T2 tumor.

hemorrhage was documented in 13 (6.4 %) patients. In seven of these, it was necessary to perform a revision in the operating room, while one patient with supraglottic cancer died on postoperative day 9 due to massive late bleeding. Temporary aspiration occurred in 19 (26 %) patients with supraglottic cancer resection (Figure 3), six of them developing postoperative pneumonia. One patient suffered heavy aspiration and recurrent aspiration pneumonia, thus total laryngectomy was performed nine months after primary ELS. In patients treated for glottic carcinoma, close follow-up revealed granulomas in ten and synechiae in seven patients. Seven patients had more than one complication.

Discussion

The incidence of complications after ELS for laryngeal and hypopharyngeal cancer ranges between 3 % and 19 %^{7,8,14}. Such a diversity in the incidence among different studies was probably influenced by different definitions of complications and different indications for ELS, which ranged from exclusively early stage carcinomas (T1 and selected T2 tumors) to the advanced laryngeal and hypopharyngeal tumors (T3, even T4 tumors)¹⁵. Generally, in most of studies, the complication rate persistently correlated with surgical experience and tumor size⁸.

Practical classification divides complications into intraoperative and postoperative (immediate and mediate), with the latter subdivided into minor and major complications⁸. Minor complications are defined as those that resolve spontaneously or with conventional outpatient treatment without any consequence, while major are those that require intensive medical treatment, blood transfusion, or revision surgery. Most studies found the average incidence of minor and major complications to be similar.

To prevent complications, it is necessary to comply with some preoperative, perioperative and postoperative rules. Excellent surgical education and skills are mandatory to reduce the incidence of complications and to resolve them successfully if they occur. In addition, appropriate preoperative patient selection according to tumor size, patient age, comorbidities and pulmonary status is crucial.

One of the most important perioperative factors is close cooperation with the anesthesiologist, which is the key for successful surgical intervention. Precise resection of the tumor and careful hemostasis are of paramount importance. It is useful to utilize cotton swab soaked with epinephrine in case of minor bleeding to keep the surgical field as clear as possible. For large vessels, use of hemostatic clips is preferred to cauterization. Otherwise, the risk of late hemorrhage increases. According to the literature, its frequency is 3–14 %, which makes the incidence of this complication similar for both endoscopic and open approach. Postoperative hemorrhage is the most serious complication, with fatal outcome in 0.3 % of patients^{4,14,16}. Late bleeding is highly dangerous because patients are usually at home without appropriate urgent medical care, thus fatal outcome is more likely to happen. In some cases of extended resection, it is useful to perform prophylactic electrocoagulation of blood vessels at the level of aryepiglottic fold. If neck dissection is performed in the same act with ELS, prophylactic ligation of the external carotid artery branches could be the method of choice. Complete ligation of external carotid artery is not recommended. In their series of 1528 patients, Ellies and Steiner had 72 (4.7 %) patients with postoperative hemorrhage. In seven cases, external carotid artery had to be ligated¹⁷. Vagal nerve and superior laryngeal nerve have to be identified and spared before any ligation.

The frequency of aspiration after partial supraglottic laryngectomy depends on the method of evaluation, so disturbances recorded in the swallowing area range between 8 and 100 %¹⁸. Open approach laryngectomies more often result in aspiration as compared with endoscopic resection; one of the reasons is transected superior laryngeal nerve that leads to weakening of the glottic closure response. Sasaki et al. demonstrated that the glottic closure reflex remained intact for 48 to 72 hours after endoscopic laser supraglottidectomy in contrast to persistent absence of this reflex in historical control patients operated on through a transcervical approach and observed for 3 weeks to 12 years after surgery¹⁹. Recently, we performed evaluation of functional deglutition in patients after partial supraglottic laryngectomy by videofluoroscopy of the swallowing act. Aspiration was recorded on videofluoroscopy in 30 % of our patients, compared to almost 90 % of patients that had undergone classic supraglottic laryngectomy²⁰.

Tracheotomy following endoscopic resection is generally not necessary. In cases of very extensive resection (especially in the elderly, or in patients with previous radiotherapy), we prefer delayed extubation instead of tra-

cheotomy, but no longer than 24 hours. Prophylactic antibiotic treatment is not recommended except for patients with large areas of exposed cartilage. Preventive placement of a feeding tube is indicated in cases of very extensive resection or in cases with the resection of one arytenoid unit. In the early postoperative period, cautious medical care and rapid postoperative mobilization of the patient are of crucial importance.

The high temperature of laser beam bears a threat of endotracheal tube ignition with a potentially fatal outcome²¹. It is considered an almost exclusively ELS-related complication, although there are a few case reports of endotracheal tube fire following open procedures, like elective tracheostomy by electrocautery²². On this background, it has lately been pointed out that laser surgery is associated with no greater risk of endotracheal tube ignition than the use of electrocautery or high frequency electrosurgery²³. Although it has been shown that even

the use of special laser tubes does not necessarily prevent all cases of endotracheal tube fire, all possible safety precautions should be considered. Adjunct maneuvers include covering the endotracheal tubes by soaked pledges or moist neurosurgical cottonoids, tube wrapping with non-inflammable tape, blocking the cuff with saline, or reduction of O₂-saturation of the narcotic gas mixture.

Conclusion

The ELS provides excellent oncologic and functional results, and is today a widely accepted method of treatment for laryngeal and hypopharyngeal cancer^{1,2}. Complication rate of the ELS is lower compared to open techniques, but strongly correlates with surgical experience, good patient selection and compliance to all recommended preoperative, perioperative and postoperative guidelines^{8,23}.

REFERENCES

1. AMBROSCH P, *Curr Opin Otolaryngol Head Neck Surg*, 15 (2007) 82. — 2. WERNER JA, DUNNE AA, FOLZ BJ, LIPPERT BM, *Cancer Control*, 9 (2002) 379. — 3. MOTTA G, ESPOSITO E, MOTTA S, TARTARO G, TESTA D, *Head Neck*, 27 (2005) 566. — 4. PERETTI G, PIAZZA C, CATTANEO A, DE BENEDETTO L, MARTIN E, NICOLAI P, *Ann Otol Rhinol Laryngol*, 115 (2006) 827. — 5. BERNAL-SPREKELSEN M, DAZERT S, SUDHOFF H, BLANCH JL, VILASECA I, *Laryngorhinootologie*, 88 (2009) 28. — 6. FRIED MP, *Laryngoscope*, 93 (1983) 275. — 7. PREUSS SF, CRAMER K, KLUSMANN JP, ECKEL HE, GUNTINAS-LICHIUS O, *Eur J Surg Oncol*, 35 (2009) 235. — 8. VILASECA-GONZALEZ I, BERNAL-SPREKELSEN M, BLANCH-ALEJANDRO JL, MORAGAS-LLUIS M, *Head Neck*, 25 (2003) 382. — 9. VAN GOGH CD, VERDONCK-DE LEEUW IM, BOON-KAMMA BA, RINKEL RN, DE BRUIN MD, LANGENDIJK JA, KUIK DJ, MAHIEU HF, *Cancer*, 106 (2006) 95. — 10. REMACLE M, VAN HAVERBEKE C, ECKEL H, BRADLEY P, CHEVALIER D, DJUKIC V, DE VICENTIS M, FRIEDRICH G, OLOFSSON J, PERETTI G, QUER M, WERNER J, *Eur Arch Otorhinolaryngol*, 264 (2007) 499. — 11. HIRANO S, *Curr Opin Otolaryngol Head Neck Surg*, 13 (2005) 143. — 12. REMACLE M, LAWSON G, MORSOMME D, JAMART J, *Otolaryngol Clin North Am*, 39 (2006) 191. — 13. SESTERHENN AM, DÜNNE AA, BRAULKE D, LIPPERT BM, FOLZ BJ, WERNER JA, *Lasers Surg Med*, 32 (2003) 384. — 14. RUDERT HH, WERNER JA, HÖFT S, *Ann Otol Rhinol Laryngol*, 108 (1999) 819. — 15. MARTIN A, JÄCKEL MC, CHRISTIANSEN H, MAHMOODZADA M, KRON M, STEINER W, *Laryngoscope*, 118 (2008) 398. — 16. CABANILLAS R, RODRIGO JP, LLORENTE JL, SUAREZ V, ORTEGA P, SUAREZ C, *Head Neck*, 26 (2004) 653. — 17. ELLIES M, STEINER W, *Am J Otolaryngol*, 28 (2007) 168. — 18. RODRIGO JP, SUAREZ C, SILVER CE, RINALDO A, AMBROSCH P, FAGAN JJ, GENDEN EM, FERLITO A, *Head Neck*, 30 (2008) 658. — 19. SASAKI CT, LEDER SB, ACTON LM, MAUNE S, *Ann Otol Rhinol Laryngol*, 115 (2006) 93. — 20. PRGOMET D, BUMBER Z, BILIĆ M, SVOREN E, KATIĆ V, POJE G, *Eur Arch Otorhinolaryngol*, 259 (2002) 399. — 21. NISKANEN M, PURHONEN S, KOLJONEN V, RONKAINEN A, HIRVONEN E, *Acta Anaesthesiol Scand*, 51 (2007) 509. — 22. AWAN MS, AHMED I, *Ear Nose Throat J*, 81 (2002) 90. — 23. SESTERHENN AM, DÜNNE AA, WERNER JA, *Acta Otolaryngol*, 126 (2006) 530.

S. Janjanin

University of Zagreb, University Hospital Center Zagreb, Department of ENT, Head & Neck Surgery, Kišpatičeva 12, 10000 Zagreb, Croatia
e-mail: s.janjanin@yahoo.com

KOMPLIKACIJE ENDOSKOPSKE CO₂ LASERSKE KIRURGIJE KARCINOMA GRKLJANA I KONCEPT NJIHOVOG ZBRINJAVANJA

SAŽETAK

Endoskopska CO₂ laserska kirurgija široko je prihvaćena metoda liječenja početnog karcinoma grkljana karakterizirana odličnim onkološkim rezultatom uz nisku učestalost komplikacija. Iako se komplikacije javljaju rjeđe nego kod otvorenih zahvata na grkljanu, one mogu biti vrlo ozbiljne, ponekad čak i smrtonosne. Javljaju se u širokom opsegu od intraoperativnog zapaljenja endotrahealnog tubusa ili krvarenja, do ranih ili kasnih postoperativnih komplikacija koje nerijetko zahtijevaju intenzivno liječenje, transfuzije krvi ili revizijsko kirurško liječenje. U radu opisujemo naše 20-godišnje iskustvo i rezultate tog tipa kirurgije, te raspravljamo o potencijalnim komplikacijama uz poseban naglasak na

koncept njihovog zbrinjavanja i sveobuhvatan pregled literature. Komplikacije su učestalije nakon endoskopskih resekcija supraglotičnih nego glotičnih tumora, a u usporedbi s otvorenim operacijama grkljana incidencija komplikacija laserske kirurgije je značajno manja. Svaki kirurg koji se upušta u endoskopsku CO₂ lasersku kirurgiju grkljana treba se držati točnih procedura kako bi se komplikacije spriječile, no istovremeno imati i jasan koncept njihovog zbrinjavanja ukoliko se razviju.